

IMAGING PERFORMED BY

IntraPet.com



Clinical Sonography & Telecytology

EDUCATIONAL TELECONSULTATION SERVICES™

1-800-838-4268 info@sonopath.com SonoPath.com

PATIENT

Fritz Egerton

SPECIES

Feline

BREED

DLH

SEX

Male Neutered

AGE

10.5.08

WEIGHT

10.1lbs

INTERPRETED BY

Maggie Machen Lamy,
DVM, DACVIM
(Cardiology)

HOSPITAL NAME

Cat Hospital at Towson

REFERRING VET

Dr. Brunt

INVOICE

29843

DATE

3.27.23

PRESENTING CLINICAL SIGNS

History: Grade 2/6 murmur appreciated. Intermittent tachypnea observed in exam room. Unregulated Hyperthyroidism.

-Pertinent abnormal PE/Chem/CBC/UA Results: Unregulated thyroid, elevated ALP, protein in urine.

-Current medications: None.

-Sedation used: Not required to complete full diagnostic ultrasound.

-Pertinent previous ultrasound results:

-STAT: Not requested

-Imaging performed by: Stephanie Warga RDCS, RVT.

ECHOCARDIOGRAM FINDINGS

2D, m-mode, color flow and doppler imaging is available. The left ventricular wall is moderately hypertrophied with regions of remodeling. There is a diffusely hyperechoic endocardium consistent with fibrosis. There is mild papillary muscle remodeling. The left atrium is mild to moderately enlarged. The right atrium is mildly enlarged. The mitral valve is normal with normal mobility. No obvious mitral regurgitation. The right ventricle appears normal. No evidence of systolic anterior motion. Blood flow through the LVOT is normal in velocity. Blood flow through the RVOT is mildly elevated with a dynamic profile. No aortic insufficiency. No TR. No pericardial or pleural effusions are visualized. No cardiac tumors seen.

CARDIAC CHART

FELINE CARDIAC PARAMETERS	BODY WEIGHT (kg)	HR (BPM)	IVSd (cm) <small>(Moise, Pipers)</small>	LVIDd (cm) <small>(Moise, Pipers)</small>	LWVd (cm) <small>(Moise, Pipers)</small>	FS (%)	EF (%)
NORMAL PARAMETER	-----	150-240	3.5-0.55	<2 (mean 1.5)	3.5-0.55	35-67	80-100
PATIENT	4.6	NM	0.72	0.92	0.73	46	81
FELINE CARDIAC PARAMETERS	LA/AO <small>(Boon)</small>	LA/AO HEART BASE (Swe) <small>(Abbott)</small>	LA 2D short axis Base view (cm) <small>(Abbott)</small>	LVOT VEL (m/s)	RVOT VEL (m/s)	E max (m/s)	
NORMAL	<1.5	<1.3	<1.2	<1.6	<1.3	<0.9	
PATIENT	NM	1.6	1.5	1.6	1.9	NM	

Adapted from June Boon, Veterinary Echocardiography, 1998
Abbott J & MacLean H JVIM 2006;20: 111-119, Moise et al. Am J Vet Res 47:1476, 1986. Pipers et al. Am J Vet Res 40:882, 1979.

INTERPRETATION OF THE FINDINGS & FURTHER RECOMMENDATIONS

Hypertrophic cardiomyopathy (HCM) is a rule out diagnosis once a patient is deemed normotensive and euthyroid. In an uncontrolled hyperthyroid cat, the finding of moderate LV hypertrophy may be primary or secondary. Serial echocardiography will be necessary to determine progression and clinical relevance in the future once the thyroid/HR are controlled. The most concerning finding is biatrial dilation. This is likely due to chronic tachycardia (tachycardia-induced cardiomyopathy causing right-sided congestive signs); however, monitoring is advised. If this is the case, BP/T4 control should resolve atrial dilation. Given these findings, I do recommend atenolol and Plavix in this case until the thyroid is well controlled. A screening BP is recommended as well, due to a combination of issues and atrial enlargement. Prognosis is guarded due to the combination of issues.

Respiratory changes are likely due to hyperthyroid disease; however, baseline CXR are strongly recommended to rule out early congestion as Lasix may be warranted.

The risk for general anesthesia is elevated with atrial dilation, and heart rate stimulating drugs such as atropine, glycopyrrolate or ketamine should be avoided unless medically necessary. With this degree of remodeling and diastolic stiffening there is a significantly elevated risk for fluid overload in this patient if needed.

Monitor at home for any change in RR/RE, exercise intolerance, and/or signs of a blood clot going forward.

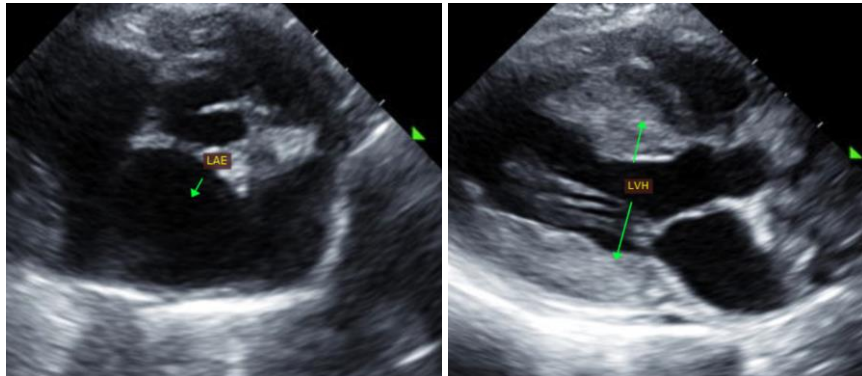
PLAN

Baseline CXR and BP are strongly recommended. Administer titrating dose of atenolol: 25mg tablets; Give ¼ tab once daily. Recheck heart rate in 1-2 weeks with target stressed rate of 140-160bpm 12-24 hours post-administration. Increase as needed until target reached. Administer anti-coagulant Plavix/Clopidogrel 75mg tabs; Give ¼ tab by mouth every 24 hours (NOTE: bitter along cut edge, may cause foaming at the mouth; coat in entirety).

Once thyroid is deemed well controlled, a brief screening of atrial dimensions is recommended. If normalized, discontinue Plavix at that time. Additionally, wean atenolol and discontinue with careful monitoring of HR once thyroid is controlled.

Recommend recheck echocardiogram 6 months post-euthyroid status to assess for progression/regression.

IMAGES



The information and recommendations provided are based on the images presented by the referring veterinarian. No evaluation can be communicated regarding pathology that was not visible in the image/video clips provided.

Thank you for this referral. This report was generated using transcription software, and minor dictation errors may be present. If the clinical or image interpretation does not parallel your findings or if I can be of any further assistance please contact me.

Maggie Machen Lamy, DVM
Diplomate of the American College of Veterinary Internal Medicine (Cardiology)
info@sonopath.com